Cervical Spine Clearance Guideline for Physicians

approved by Trauma Committee (8/24/04)

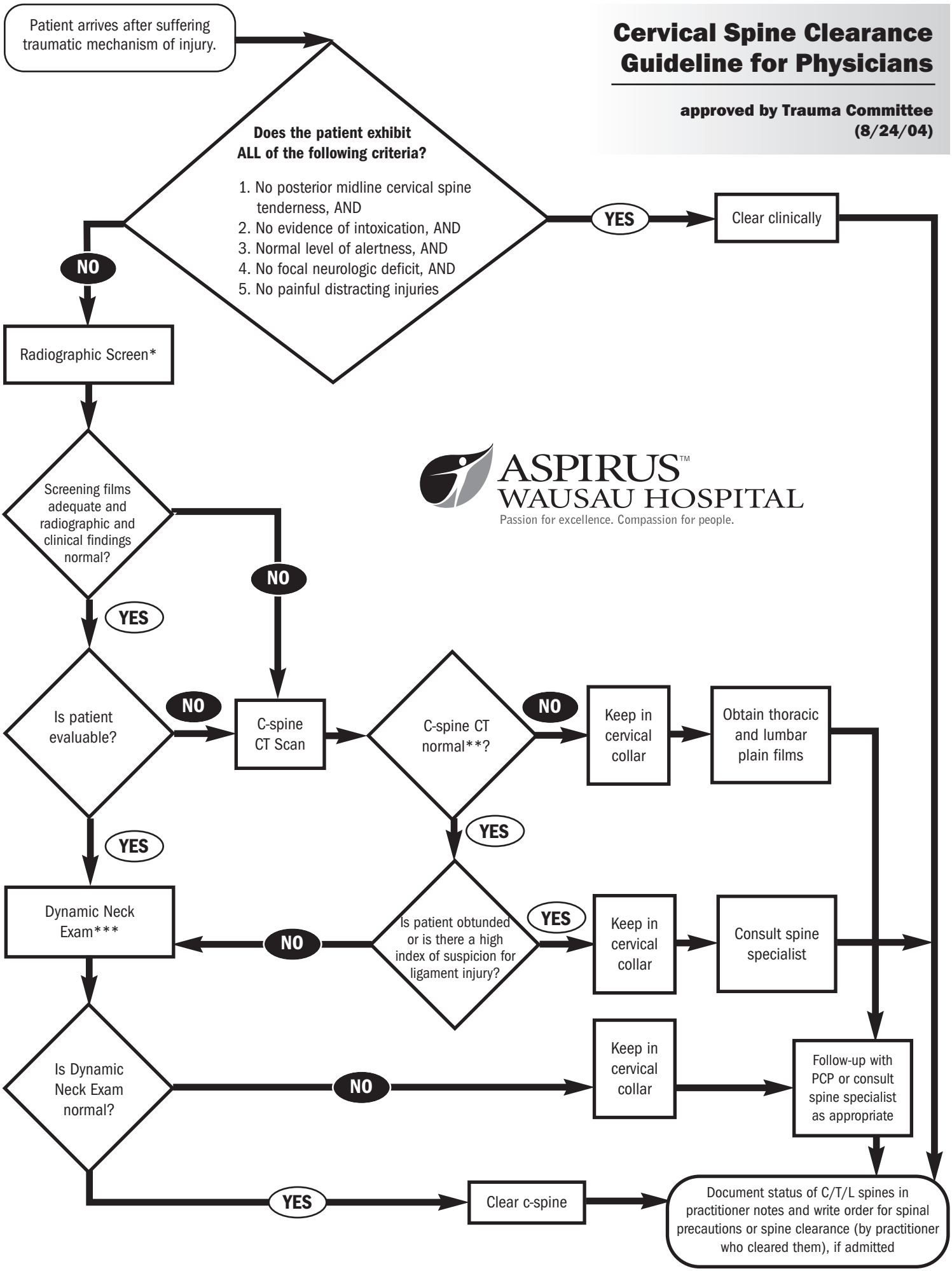

ASPIRUS™ WAUSAU HOSPITAL

Passion for excellence. Compassion for people.

ASPIRUS™
WAUSAU HOSPITAL
Passion for excellence. Compassion for people.

***Radiographic Screen of C1-T1 can be plain films or CT:**

- 3-view cervical spine series
  - cross-table lateral view (CTLV)
  - anteroposterior (AP)
  - open-mouth odontoid view

  If inadequate visualization of C1-T1, obtain swimmer's view of oblique views as needed
  CT may be necessary
- CT of cervical spine
  At the discretion of the treating physician, but not limited to the following:
  - Patients with persistent midline spine tenderness despite normal plain films
  - If perceived delays in obtaining plain films may compromise patient management in the ED (compared to more expedient CT)
  - Severely injured patients at high risk for cervical spine injury
  - Obtunded patients (GCS </= 13)
  - Intubated patients (presence of ET tube may alter the radiographic appearance of upper cervical anatomy)
  - Patients with neurological deficits (consider MRI within 2 hours of ED arrival)
  - Patients with underlying cervical spine abnormalities (prior surgery, previous c-spine injury, advanced DJD, rheumatoid arthritis, ankylosing sponylitis, etc.)

**** "Normal" CT**

No evidence of significant cervical spine injury. Anything but:

- small chip fracture of body
- spinous process fracture

*****Dynamic Neck Exam**

Once the neurological examination is proven normal, a dynamic (range of motion) evaluation of the neck should be undertaken to assess the mobility of the cervical spine. If the dynamic exam produces no tenderness or sensory/motor deficits, the cervical spine is considered clinically clear of potential injury. If motion produces tenderness or neurologic deficits (even if transient), cervical stabilization should be maintained and further radiographic evaluation pursued

References.

1. "Cervical Spine Injury: A State-Of-The-Art Approach to Assessment and Management". Emergency Medicine Practice, An Evidence-based Approach to Emergency Medicine. http://www.empractice.net. 05/31/04.
2. Diaz, J. et al. Are Five-View Plain Films of the Cervical Spine Unreliable? A Prospective Evaluation in Blunt Trauma Patients with Altered Mental Status. Journal of Trauma. 2003 Oct;55(4):658-664.
3. Griffen, M. et al. Radiographic Clearance of Blunt Cervical Spine Injury: Plain Radiograph or Computed Tomography Scan? Journal of Trauma. 2003 Aug;55(2):222-227.
4. Panacek, E. et al. Test Performance of the Individual NEXUS Low-Risk Clinical Screening Criteria for Cervical Spine Injury. Annals of Emergency Medicine. 2001 July;38(1):22-25.
5. Hoffman, J. et al. Validity of a Set of Clinical Criteria to Rule Out Injury to the Cervical Spine in Patients with Blunt Trauma. The New England Journal of Medicine. 2000 July;343(2):94-99.
6. Determination of Cervical Spine Stability in Trauma Patients (Update of the 1997 EAST Cervical Spine Clearance Document). Eastern Association For The Surgery of Trauma.